

POST-STROKE DELUSIONAL DISORDER — WHAT SHOULD A PRIMARY CARE PHYSICIAN KNOW?

Dr Elin Lee, Dr Chris Tsoi, Dr Ong Chooi Peng

ABSTRACT

Cerebrovascular diseases are one of the leading causes of death in Singapore and worldwide. Post-stroke neuropsychiatric disorders such as depression and anxiety disorders are common and there have been primary care articles highlighting the need for general practitioners to actively monitor patients for neuropsychiatric sequelae such as post-stroke depression.

There is however a scarcity of primary care articles on post-stroke delusional disorder. Though post-stroke delusional disorders are uncommon, primary care physicians should be equipped to not only be able to manage common diseases well but also uncommon presentations of common diseases, as they can cause significant morbidity and mortality.

We present a pilot case report on a middle-aged Chinese gentleman with a rare occurrence of post-stroke delusional disorder that presented and was managed in the community setting in Singapore.

SFP2016; 42(4): 77-79

Case Report

Patient's revelation: “The Taiwanese Police are after me. What do I do?”

Mr. L, a 59-year-old Singaporean Chinese male with no significant medical or psychiatric history, presented with a complaint that he was being chased by the Taiwanese Police for arrest. This occurred on 21 July 2015, the day he was stepped down to a community hospital for rehabilitation following a three-week admission in an acute hospital for intraventricular haemorrhage (IVH) secondary to right arteriovenous malformation (AVM) status post extraventricular drain insertion.

“I’m here as I have murdered a doctor in this community hospital! I will be sentenced to death on the 27 July 2015 for my crime!”

ELIN LEE

Family Medicine Residency Programme,
National University Hospital System (NUHS), Singapore
Ministry of Health Holdings (MOHH), Singapore

CHRIS TSOI

Family Medicine Residency Programme,
Visiting consultant, St Luke’s Hospital
Consultant, Department of Psychological Medicine,
National University Hospital (NUH)
Programme Director, Geriatric Psychiatry
Out-Reach Assessment, Consultation and Enablement (G-RACE)

ONG CHOOI PENG

Visiting consultant, St Luke’s Hospital

Mr. L believed that he had been placed in the community hospital as he was being held under arrest by the Taiwanese Police for the murder of a doctor there even though he had only arrived at the community hospital. He also believed that he would be sentenced to death on 27 July 2015.

A corroborative history with his wife revealed that Mr. L had no psychiatric symptoms prior to the transfer to the community hospital. He also had no prior history of psychiatric disorders. His work mainly involved frequent travels for business purposes, and his mood was good and he was not under any stressors. For the entire time Mr. L was in the community hospital, he was under the care of the nurses.

There was associated thought block (inability to recall) and marked affective symptoms. The significant affective symptoms were demonstrated when, at the thought of 27 July 2015, Mr. L would start crying even though he understood that it was not reasonable. However, there were no auditory and visual hallucinations or beliefs that were parasitic, referential, grandiose, erotomanic, nihilistic or somatic in nature. Mr. L’s belief caused him great fear and he was unable to sleep. Interestingly, he acknowledged that this belief did not make sense but at the same time was unable to let go of it as it were held deeply in his mind. Abbreviated Mental Test (AMT) and Mini-Mental State Examination (MMSE) scores were 9 out of 10 and 26 out of 30, respectively.

Differentials of delirium and new cerebrovascular accident (CVA) were considered. However, Mr. L did not meet the Confusion Assessment Method (CAM) diagnostic criteria for delirium. His symptoms though acute, were not fluctuating and there was no associated inattention, disorganised thinking or altered level of consciousness. Urinalysis and electrocardiogram performed as part of delirium work-up were unremarkable. No further blood tests were done as the full blood count and electrolytes were normal one day prior to the onset of delusions. There were also no new neurological symptoms or signs (e.g. weakness, numbness, seizures) suggestive of a new stroke. Serial computed tomography (CT) brain scans done in the acute hospital also showed the brain haemorrhages resolving.

Mr. L did not have any constitutional (loss of appetite or weight) or infective (fever and localising features) symptoms or signs. There was no evidence of metabolic disorders (hypercalcaemia, hyponatremia, hypoglycaemia, uraemia, hepatic encephalopathy or porphyria), endocrinopathies (Addison disease, Cushing syndrome, hyper- or hypothyroidism or panhypopituitarism), vitamin deficiencies (vitamin B-12, folate, thiamine or niacin), long-term medications (adrenocorticotrophic hormones, anabolic steroids, corticosteroids or cimetidine) antibiotics (cephalosporins, penicillin, disulfram or anticholinergic)

substance abuse (amphetamines, cocaine, alcohol, cannabis or hallucinogens) or exposure to toxins (mercury, arsenic, manganese or thallium).

Mr. L was diagnosed with organic delusional disorder secondary to CVA. Olanzapine was commenced and Mr. L's symptoms resolved two weeks after. He was advised to continue olanzapine for another six months with a plan to wean off during psychiatric follow-up.

Gaining insight: What are the issues?

1. What is a delusion?
2. What is the prevalence of primary care articles on post-stroke delusions?
3. How important are clinical skills in the diagnosis of post-stroke delusional disorder?
4. What is the management of post-stroke delusional disorder?
5. What are the possible complications of post-stroke delusional disorder?

Study the management: How do we apply in our clinical practice?

A delusion is an idiosyncratic belief or impression maintained despite being contradicted by reality or rational argument. In the case of Mr. L, he strongly believed that he was being pursued by the Taiwanese Police as he had murdered a doctor in the community hospital even though corroborative history with his wife, nurses, and doctors in the community hospital suggests otherwise. Persecutory type delusions post-stroke such as in Mr. L are commonly seen, evident in a study that reported 67 percent of its post-stroke delusions as persecutory.¹ However, they could also present as delusions involving bodily perception² or even be parasitic³ in nature.

Although Mr. L has no psychiatric illness, pre-existing mental

health problems have been highlighted as a potential factor in generating post-stroke psychotic symptoms.⁴ Post-stroke psychosis is rare. The reason this is so has been postulated to be that more than one focus of abnormality has to be present for delusional ideas to become severe enough to clinically manifest.⁴ The first "hit" could have been the untreated underlying mental health problems and the second "hit" the stroke, causing the manifestation of psychotic symptoms.⁴ Creating awareness of the possible different types of delusions that can present post-stroke and the association with an underlying psychiatric disorder will remind primary care physicians to actively seek out psychotic symptoms when following-up the care of a stroke patient with a history of mental health problems.

Cerebrovascular diseases are the fourth leading cause of death in Singapore⁵ and the second leading cause of death worldwide.⁶ Neuropsychiatric disorders are common after stroke, with possible depression, anxiety disorders, emotional incontinence, and catastrophic reactions;⁷ depression being the most common at a prevalence of 29 percent.⁸ Khan highlighted the need for general practitioners to actively monitor patients for post-stroke depression (PSD), as untreated PSD can interfere with recovery and adversely affect functional and social outcomes, viz. greater disability with activities of daily living, poor participation in rehabilitation, reduced social activity and a higher mortality at 10 years.⁹

There is however a scarcity of primary care articles on post-stroke delusional disorder. Though post-stroke delusional disorders are uncommon with an incidence of 4 percent,¹ primary care physicians should be equipped to detect uncommon manifestations of common disease.¹⁰ This case highlights how a rare complication of stroke can present in the community setting and how a community physician who correctly started olanzapine prior to assessment by the specialist, expedited the

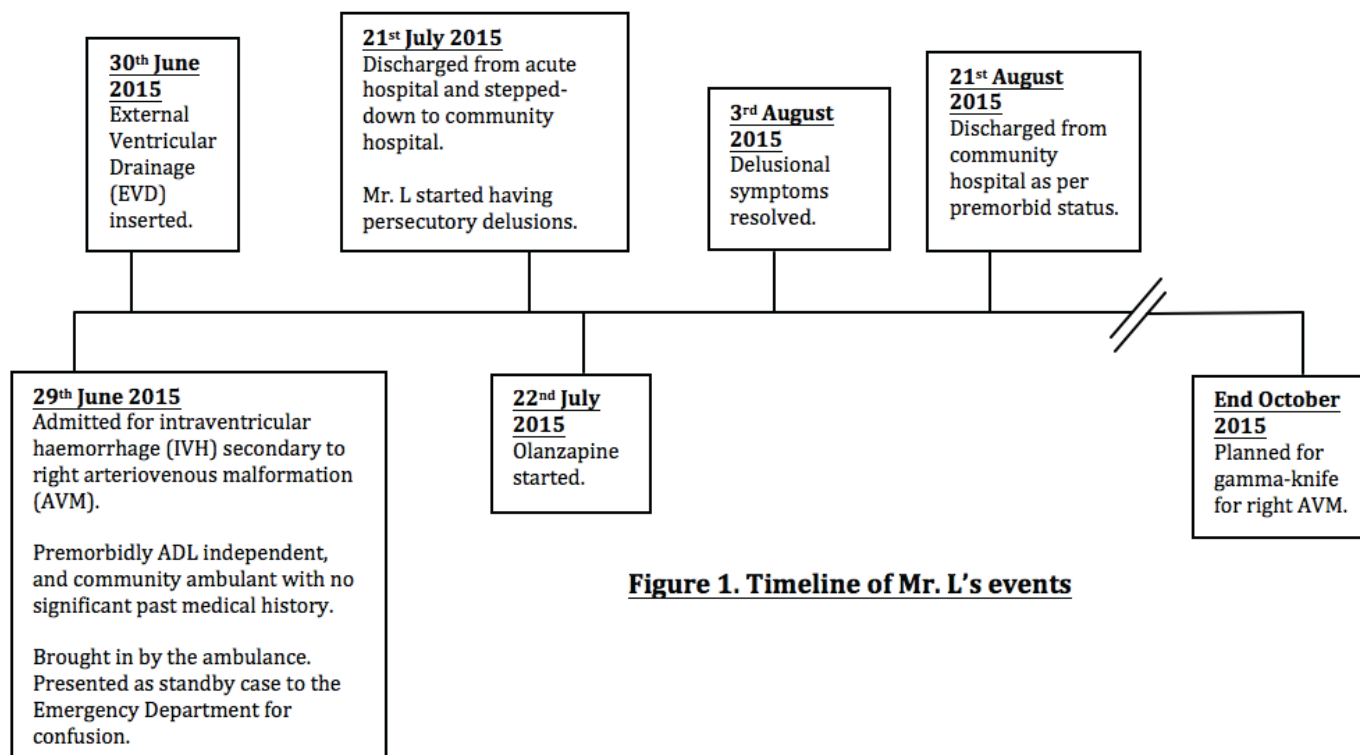


Figure 1. Timeline of Mr. L's events

patient's recovery. Philips concluded that primary care physicians played an important role in the care of patients with rare medical problems via provision of a broad range of services including diagnosis, treatment, referral, and long-term patient management.¹⁰

This case also highlighted the importance of having good clinical skills. With advances in modern medicine, there has been a trend of over-reliance on investigations, thus reducing clinical awareness and skills. Sophisticated investigative methods extend the capacity of the doctors to serve the patient, are adjuncts to the human relationship between doctor, nurse, and patient, and do not replace the art.¹¹ Investigations should be prompted by suspicion after history taking and clinical examination. Often, the clinical diagnosis can be made after a careful history, competent physical examination, and identification of salient features. This was exemplified in this case, where the identification of co-existing partial insight with delusions, and quick resolution of symptoms after commencement of an anti-psychotic, in the presence of relevant neuroimaging helped support the diagnosis of post-stroke delusional disorder. This reduced further cost of ordering unnecessary laboratory tests and imaging. Effective primary care practice relies heavily on clinical skills. A good primary care physician will need to possess clinical acumen and the ability to choose relevant investigations.

Mr. L had no risk factors for stroke, typically diabetes, hypertension, and hyperlipidaemia. In patients who do, the management for post-stroke psychosis should involve the modification of risk factors for stroke on top of the psychotropic medications targeting the psychiatric symptoms.¹² In a recent review, type 2 diabetes mellitus has been shown to cause inflammation and to disrupt the blood brain barrier permeability, leading to leakage of inflammatory cytokines into the brain, possibly resulting in neuro-psychiatric manifestations.¹² Depression has also been linked to inflammatory pathways. Hypertension has been associated with depression, anxiety, and dementia. It can cause vascular changes resulting in lacunar infarcts and white-matter hyperintensities on brain imaging. It can also influence beta-amyloid accumulation, affecting neuronal synapses and formation of senile plaques.¹²

Lastly, it is important to monitor post-stroke psychosis patients closely as it is associated with high morbidity and mortality. One reason is the use of anti-psychotics, as the brain is more vulnerable to developing side effects.¹² Cognitive function monitoring is encouraged, as these patients are prone to developing dementia and other psychiatric illness.¹² There is doubled mortality during the subsequent 10 years compared to post-stroke controls with no mental disorders seen in a cohort by Almeida and Xiao,¹³ though the underlying mechanisms have yet to be confirmed. Devastating effects of suicide and homicide¹³ secondary to persecutory delusions can occur if these are not treated promptly.

CONCLUSION

Post-stroke delusional disorder, although uncommon, is an important clinical condition to be aware of because of the associated high morbidity and mortality. Primary care physicians need to be trained not only to manage common diseases well but also uncommon presentations of common diseases appropriately.

Acknowledgement

Prof. Goh Lee Gan who kindly provided invaluable advice and pearls of wisdom to this case report.

REFERENCES

1. Kumral E, Ozturk O. Delusional state following acute stroke. *Neurology*. 2004;62:110–3.
2. Levine DN, Grek. The anatomic basis of delusions after right cerebral infarction. *Neurology* 1984;34:577–82.
3. Adunsky A. Early post-stroke parasitic delusions. *Age Ageing*. 1997;26:238–9.
4. Devine MJ, Bentley P, Jones B, Hotton G, Greenwood RJ, Jenkins IH, et al. The role of the right inferior frontal gyrus in the pathogenesis of post-stroke psychosis. *J Neurol*. 2014;261:600–3.
5. Ministry of Health. Principle causes of death. Singapore: Ministry of Health; 2015.
https://www.moh.gov.sg/content/moh_web/home/statistics/Health_Facts_Singapore/Principal_Causes_of_Death.html.
6. Goulart AC, Bustos IR, Abe IM, Pereira AC, Fedeli LM, Bensenor IM, et al. A stepwise approach to stroke surveillance in Brazil: The EMMA (Estudo de Mortalidade e Morbidade do Acidente Vascular Cerebral) study. *Int J Stroke*. 2010;5:284–9.
7. Chemerinski E, Levine SR. Neuropsychiatric disorders following vascular brain injury. *Mt Sinai J Med*. 2006;73:1006–14.
8. Ayerbe L, Ayis S, Wolfe CD, Rudd AG. Natural history, predictors and outcomes of depression after stroke: systematic review and meta-analysis. *Br J Psychiatry*. 2013;202:14–21.
9. Khan F. Poststroke depression. *Aust Fam Physician*. 2004;33:831–4.
10. Phillips WR. Zebras on the commons: rare conditions in family practice. *J Am Board Fam Pract*. 2004;17:283–6.
11. Goodwin J. The importance of clinical skills. *BMJ*. 1995;310:1281–2.
12. Khadijah HAA, Suriati MS, Shalisah S, Abdul Hamid AR. Psychosis post corona radiata and lentiform nucleus infarction. *BMJ Case Reports*. 2015. doi:10.1136/bcr-2014-2089543.
13. Almeida OP, Xiao J. Mortality associated with incident mental health disorders after stroke. *Aust N Z J Psychiatry* 2007;41:274–81.